












Can Adolescent Idiopathic Scoliosis be Associated with Visual Impairment?

 Sabri Batın,¹  İlyas Uçar,²  Ahmet Payas,^{3*}  Emre Bal,⁴  Yakup Ekinci,¹
 Erdal Kurtoğlu,²  Mustafa Arık,⁵  Turgut Seber,⁶  Halil Yılmaz,⁷  Nisa Kahraman,⁸
 Erdoğan Unur²

¹Department of Orthopedics and Traumatology, Kayseri City Training and Research Hospital, Kayseri, Türkiye

²Department of Anatomy, Erciyes University Faculty of Medicine, Kayseri, Türkiye

³Hitit University, Vocational College of Sungurlu, Çorum, Türkiye

⁴Department of Orthopedics and Traumatology, Fatih Sultan Mehmet Training and Research Hospital, İstanbul, Türkiye

⁵Department of Orthopedics and Traumatology, Aksaray Ortaköy Public Hospital, Aksaray, Türkiye

⁶Department of Radiology, Kayseri City Training and Research Hospital, Kayseri, Türkiye

⁷Department of Anatomy, Ordu University Faculty of Medicine, Ordu, Türkiye

⁸Department of Ophthalmology, Kayseri City Training and Research Hospital, Kayseri, Türkiye



*The current affiliation of the author: Department of Anatomy, Amasya University Faculty of Medicine, Amasya, Türkiye

Cite this article as:

Batın S, Uçar İ, Payas A, Bal E, Ekinci Y, Kurtoğlu E, et al. Can Adolescent Idiopathic Scoliosis be Associated with Visual Impairment? J Clin Pract Res 2023; 45(4): 385–91.

Address for correspondence:

Ahmet Payas.
Department of Anatomy,
Amasya University Faculty of
Medicine, Amasya, Türkiye
Phone: +90 358 211 50 05
E-mail: fizyopayass@gmail.com

Submitted: 29.03.2023

Revised: 22.05.2023

Accepted: 22.06.2023

Available Online: 12.07.2023

©Copyright 2023 by Erciyes
University Faculty of Medicine -
Available online at www.jcpres.com

ABSTRACT

Objective: It is believed that postural balance problems may contribute to the development of adolescent idiopathic scoliosis (AIS). Vision provides proprioceptive input by supplying information about body positions. Considering the fundamental role of vision in postural control, this study aims to investigate the relationship between AIS and the volume of the eye-moving muscles and the visual field.

Materials and Methods: This prospective cross-sectional study included a total of 47 female individuals, with 24 having AIS and 23 being healthy participants. Magnetic resonance imaging was used to calculate the volumes of the medial rectus (MR) and lateral rectus (LR) muscles in both groups. Additionally, the visual field test was conducted to determine the pattern standard deviation (PSD) and mean deviation (MD) values for the left and right eyes of individuals in both groups.

Results: The mean age of AIS patients with a major curvature of 48.50 degrees and a Lenke Type-1 curve was similar to that of asymptomatic individuals. The volume values of the MR muscle on both sides were lower in the AIS group compared to the control group ($p<0.05$). Significant differences were found in the PSD values of the visual field test within the AIS group ($p<0.01$). However, there was no significant difference in the MD values between the left and right eyes of the two groups ($p>0.05$).

Conclusion: It is important to consider the presence of visual sensory defects in individuals with AIS. It is unknown whether AIS causes visual impairment or vice versa. Therefore, further comprehensive studies are needed.

Keywords: Adolescent, idiopathic scoliosis, visual field, balance, eye muscles.



INTRODUCTION

Adolescent idiopathic scoliosis (AIS) is the most common type of scoliosis, particularly affecting adolescent girls.¹ Despite numerous studies, the exact cause of AIS remains unclear.² Several studies have proposed that balance issues may contribute to the development of scoliosis.^{2–4} Postural balance relies on the integration of visual, somatosensory, and vestibular systems.⁵ Vision not only provides information about the position of body movements relative to the environment or a body part but also contributes to both exteroceptive and proprioceptive input.⁶ Studies suggest that an inadequate visual or oculomotor system can lead to scoliotic deformities.^{3,7,8} However, there is currently insufficient objective evidence on this subject is.¹

Defective vision encompasses conditions such as eye movement disorders, impaired central vision, impaired peripheral vision, visual inattention, and visual perception disorders.⁹ Several studies have demonstrated that the head and neck muscles can adapt to postural changes, including scoliosis.¹⁰ Given the fundamental role of vision in postural control, it is worth exploring the relationship between scoliosis, the visual field, and the muscles responsible for eye movement, based on objective data. Thus, our aim was to analyze the potential relationship between eye muscle size, visual field, and scoliosis using absolute values. This was accomplished by calculating the visual field and eye muscle volume in individuals with AIS and healthy individuals.

MATERIALS AND METHODS

Ethical Considerations

Ethics committee approval for the study was obtained from Kayseri City Hospital, with a decision dated 02/12/2021 and numbered 539. The study was conducted in accordance with the provisions of the Declaration of Helsinki, and pre-study consent was obtained from all participants.

Participants and Study Groups

The study included individuals diagnosed with AIS and healthy individuals between March 2021 and March 2022. The diagnoses were made by an orthopedist (BS) with at least 10 years of experience in treating scoliosis and who determined the need for surgical intervention. Inclusion criteria were as follows: diagnosis of Main Thoracic-Lenke type-1 (Right thoracic) AIS, major curvature angle of 45° and above, age between 10-18, and female gender. Control group inclusion criteria consisted of the absence of any neurological or orthopedic disease and the absence of the need to wear lenses or glasses.

Exclusion criteria for both groups were a history of spine-related trauma or surgery and the presence of neuromuscular disease. Healthy individuals with significant eye diseases requiring the use of glasses were also excluded.

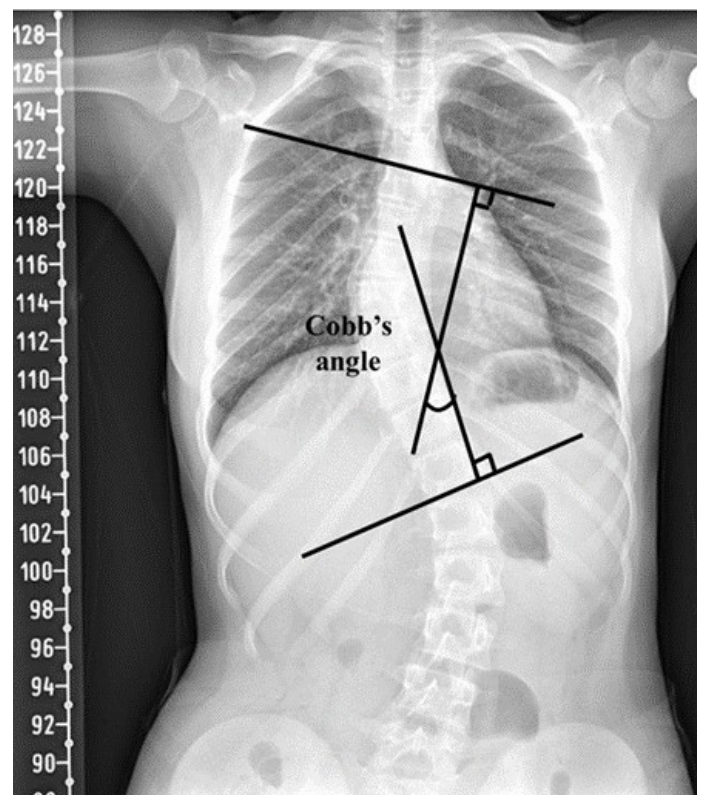


Figure 1. Calculation of major curvature angle in scoliosis.

For this study, a statistically significant level of 5% ($p=0.05$) was chosen, with a statistical power of 80% and an effect size of 0.8. Based on these parameters, a minimum of 21 participants was required for each group.

AIS group (n=24): This group comprised individuals diagnosed with AIS in our clinic who had an indication for surgical treatment.

Control group (n=23): Asymptomatic participants between the ages 10–18 were included in this group. After evaluation by an orthopedist, individuals without any musculoskeletal diseases were selected.

The study collected information on the age, height and weight of the participants. The Body Mass Index (BMI) of all participants was calculated using the formula $[BMI = \text{Weight}/(\text{Height} \times \text{Height}) \text{ (kg/m}^2\text{)}]$.

Measurement of the Major Curvature Angle in Scoliosis

The curvature angle of the spine in the frontal plane for individuals with AIS was measured by the radiologist (ST) and the orthopedist (BS), and the average of the two measurements was taken. Individuals with a major curvature angle of $\geq 40^\circ$ were included in the AIS group (Fig. 1).

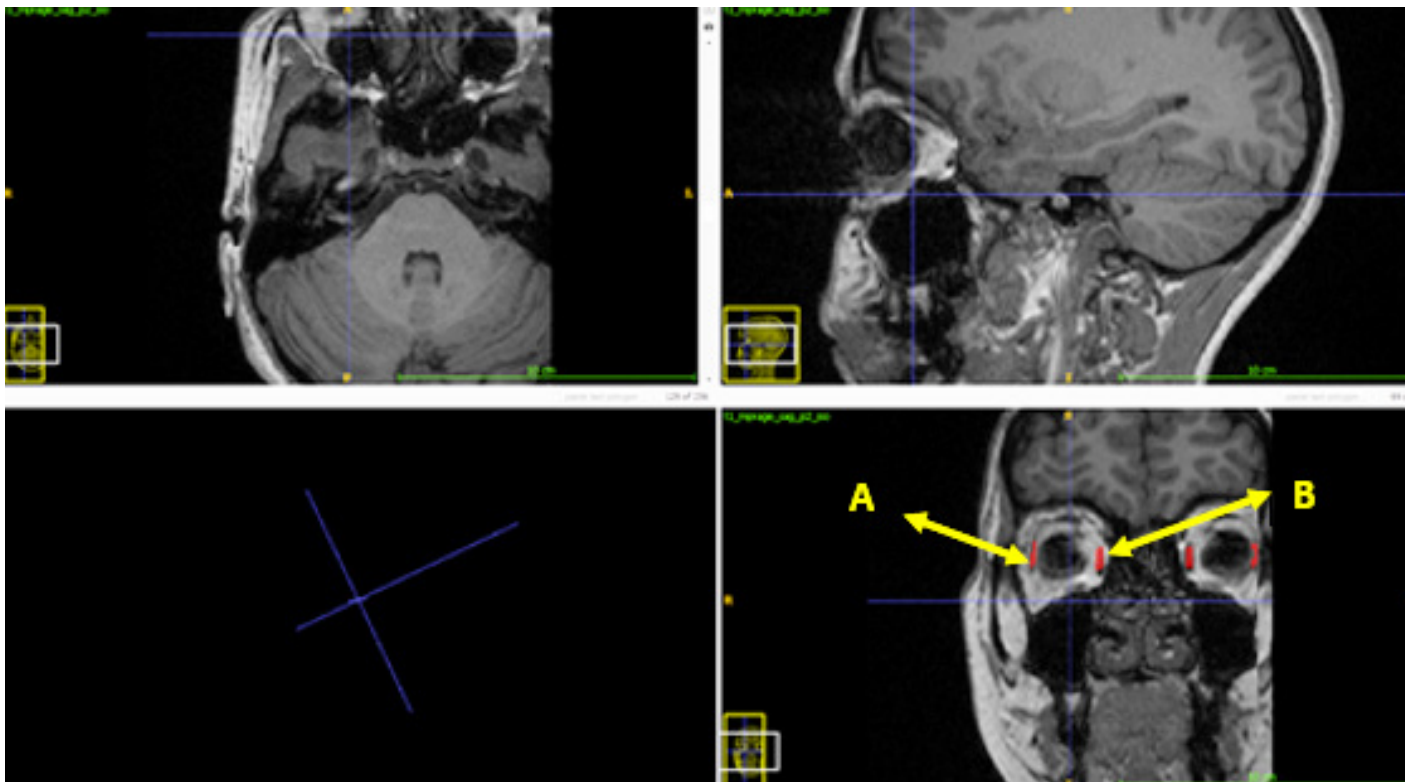


Figure 2. Volume calculation of eye muscles. (a) Lateral rectus muscle. (b) Medial rectus muscle.

Volume Calculation of Eye Muscles Using Cranial Magnetic Resonance Imaging (MRI)

Brain MRIs of the participants were obtained using Siemens Skyra brand (Germany) 3T MR devices. T1-weighted 3D Magnetization Prepared Fast Gradient Echo (MPRAGE) sequence was used to capture anatomical structures. The MR sequence settings were as follows: FOV=250×250 mm², TR/TE=2300/3.4 ms, acquisition matrix=256×256, number of slices=172, slice thickness=1.0 mm, and flip angle=9°.

To determine the volume of the lateral rectus (LR) and medial rectus (MR) muscles in the study, MRIs with a slice thickness of 0.1 mm were converted to JPEG format. The resulting JPEG images were opened using the “ImageJ” program. The “image to stack” option under the “image” tab in ImageJ was used to create an image series from the opened images. Prior to measuring, calibration was performed in the ImageJ program. The length of the image opened in RadiAnt was measured using the “measurement and tools” option, and then the length of the measurement site was marked with the “straight” option in ImageJ. The calibration process was completed using the “Set Calibrate” function in the “analyze” tab of the ImageJ program. The borders of the LR and MR muscles were manually determined in all sections contain-

ing these muscles using the “Free Hand” option in ImageJ. The surface area of each section was calculated using the “M” key. The volumes of the measured muscles were obtained by summing the area values of each section and multiplying by the section thickness of the image. All these procedures were recorded separately on MRI for both sides of the LR and MR muscles in each individual. Volume measurements were conducted separately by a radiologist (ST) and an anatomist (PA), and the mean of the values obtained was used for statistical analysis (Fig. 2).

Evaluation of the Visual Field

A visual field test was performed on the participants by an ophthalmologist (KN) with at least ten years of experience in the field. All participants did not wear contact lenses or glasses. The following global values were used as the basis for evaluating the visual field of the participants. Mean Deviation (MD) is a measure that compares all tested points with the normal reference visual field. It indicates whether the tested visual field is lower or higher than the normal visual field. An increase in MD suggests generalized depression or significant loss of one part of the visual field compared to the other (Fig. 3). Pattern Standard Deviation (PSD) provides the standard deviation of the difference between the expected normal value in indi-

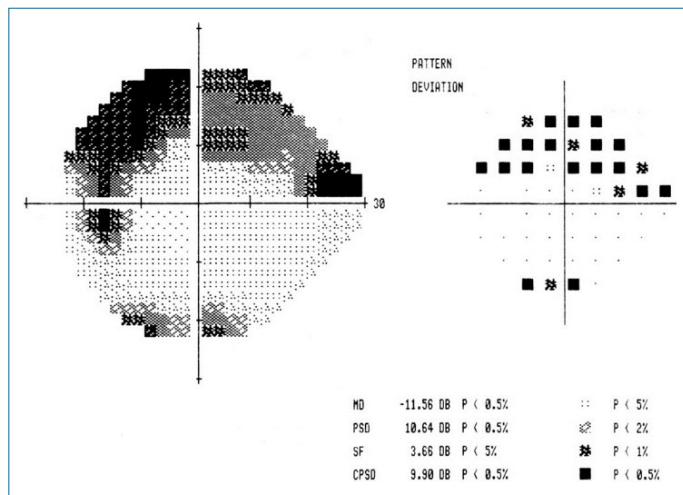


Figure 3. Mean deviation (MD).

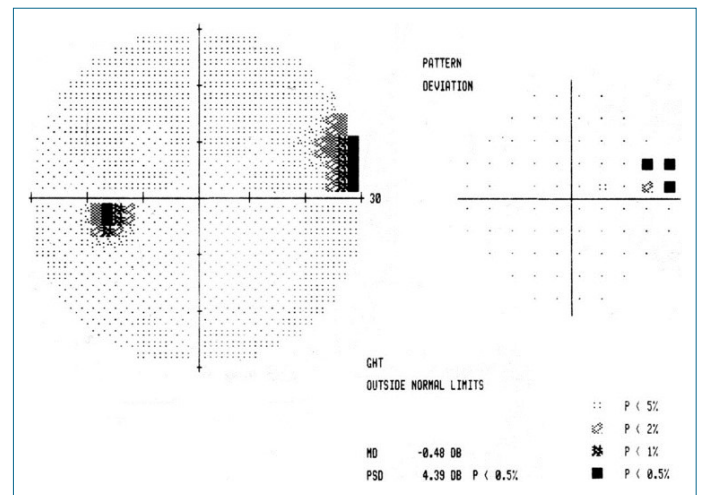


Figure 4. Pattern standard deviation (PSD).

viduals and the value measured during the test. It indicates the extent to which the measured visual field shape deviates from the normal age-corrected visual field. A low PSD reflects a smooth visual field profile, while a high PSD indicated an irregular visual field profile (Fig. 4).

Statistical Analysis

Five parameters were considered for the normal distribution analysis of the research data: Skewness-Kurtosis, Standard Deviation (Std)/Mean, Q-Q Plots, Histogram, and Shapiro Wilk Test. Parameters were considered to be normally distributed when their normal distribution score (NDS) was greater than three. For normally distributed parameters, they were presented as mean±standard deviation (SD). Independent Samples T Test was used to compare two independent groups, while the Related Samples T Test was employed for comparisons within dependent groups. Pearson correlation analysis was conducted for parametric data. Nonparametric parameters were identified when their NDS≤3 and were presented as median [Interquartile Range (IQR)]. The Mann-Whitney U test was used to compare two independent groups, and Spearman’s correlation analysis (Spearman Rho) was employed for correlation analysis. A significance level of α=0.05 was considered, with p<α deemed significant. The statistical analysis of this study was performed using IBM Statistical Package for the Social Sciences (SPSS) 23.00 software.

RESULTS

The AIS group consisted of female patients with Lenke Type-1 (right thoracic) scoliosis, with a mean major curvature angle of 48.50 degrees and a mean age of 14.90±1.94 years. The mean age of asymptomatic individuals was 14.81±2.77 years (Table 1).

Eye Muscle Volumes

The left MR values of the scoliosis group were 8.57% smaller than those of the control group. The difference in left MR parameters between the control and AIS groups was statistically significant (p<0.05). The right MR values of the AIS group were 10.79% smaller than those of the control group. A significant difference was found in the right MR volumes between the AIS and control groups (p<0.01) (Table 1). Additionally, while there was no significant difference between the left MR and the right MR in the control group (p>0.05), this difference was found to be significant in the 95% confidence interval in the AIS group (p<0.05) (Table 2).

Evaluation of the Visual Field

While there was no difference in the left and right PSD values in the control group (p>0.05), there was a difference in the AIS group (p<0.01). There was a significant difference between the AIS and control groups in both the right and left PSD values (p<0.05). There was no significant difference between the AIS and control groups in both the right and left values of the MD and tractus opticus (p>0.05).

DISCUSSION

This study observed that the muscle imbalance seen in the paravertebral muscles of individuals with scoliosis also existed in the eye muscles. Asymmetry in the visual muscles may contribute to explaining the cause of visual impairment, which is often seen in scoliosis cases.

The etiopathogenic mechanism of AIS has not yet been defined. However, most authors suggest that AIS may be caused by genetic, hormonal, biomechanical, and neurosensory factors.^{11,12}

Table 1. Comparison between groups

	Control group	AIS group	Sig. (p)
Age	14.81±2.77	14.90±1.94	0.901
Weight	49.45±7.65	49.40±6.85	0.984
Height	1.55±0.11	1.55±0.09	0.988
Body mass index	20.43±1.73	20.49±2.52	0.920
Left medial rectus muscle (MR)*	443.06±44.56	408.28±55.04	0.026
Left lateral rectus muscle (LR)	374.14±27.87	368.84±60.72	0.712
Right medial rectus muscle (MR) **	431.63±40.30	389.63±56.79	0.007
Right lateral rectus muscle (LR)*	339.11±55.72	364.35±75.80	0.069
Left tractus opticus	32 (1–149)	43 (1–212)	0.698
Right tractus opticus	14 (1–111)	13 (1–105)	0.681
Left mean deviation (MD)	1.76 (0.66–8.11)	2.33 (1.27–3.61)	0.073
Left pattern standard deviation (PSD)*	1.60 (1.10–6.09)	2.07 (1.27–3.61)	0.023
Right mean deviation (MD)	1.85 (0.09–11.65)	2.27 (0.99–4.69)	0.146
Right pattern standard deviation (PSD)**	1.71 (1–6.72)	2.735 (1.57–4.56)	0.009

*: Parametric data were shown as mean±standard deviation (SD), and the Independent Samples T Test was used for statistical analysis. **: Non-parametric data were shown as median (IQR), and the Mann-Whitney U Test was applied in pairwise comparisons.

Table 2. Intra-group comparison

	Control group	Sig. (p)	AIS group	Sig. (p)
Left medial rectus muscle (MR) volume	443.06±44.56	0.103	408.28±55.04	0.032
Right medial rectus muscle (MR)	431.63±40.30		389.63±56.79	
Left lateral rectus muscle	374.14±27.87	0.001	368.84±60.72	0.706
Right lateral rectus muscle	319.11±55.72		364.35±55.80	
Left pattern standard deviation (PSD)	1.60 (1.10–6.09)	0.144	2.07(1.27–3.61)	0.003
Right pattern standard deviation (PSD)	1.71 (1–6.72)		2.73 (1.57–4.56)	
Left mean deviation (MD)	1.76 (0.66–8.11)	0.516	2.33 (1.27–4.48)	0.570
Right mean deviation (MD)	1.85 (0.09–11.65)		2.27 (0.99–4.69)	
Left tractus opticus	32 (1–149)	0.011	43 (1–212)	0.027
Right tractus opticus	14 (1–111)		13 (1–105)	

Parametric data were shown as mean±standard deviation (SD), and the Related Samples T Test was used for statistical analysis. Non-parametric data were shown as median (IQR), and the Wilcoxon Test was applied in pairwise comparisons.

Although there are studies reporting head and neck asymmetry in patients with spinal deformity,¹³ we have not found any study examining the effect of head and neck asymmetry on the morphological structure of the eye muscles and visual field.

It has been suggested that deterioration in postural stability affects the onset and progression of AIS.¹⁴ Postural stability is provided by the formation of postural tone and postural reflexes as a result of the healthy transmission of vestibular, visual, and

somatosensory senses to the brain.¹⁵ When a healthy individual describes the relative position of any part of the body in space, they combine visual stimulation with proprioceptive information from that area. Therefore, the proprioceptive power of the visual sense is of great importance in all motor activities such as walking, running, and cycling.¹⁶ Studies claim that vision is not only a simple and complementary phenomenon that aids proprioception but also one of the most powerful possible sources of proprioceptive information.^{16–18} While the proprioceptive sense

gives information about the stimuli coming from the body, the visual sense gives information about the stimuli coming from the environment outside the body. Information from both senses comes together at a certain level and plays a role in maintaining posture.¹⁸ de Pádua et al.¹⁹ reported that vision problems affect postural balance. In individuals with visual impairment, they reported abnormalities such as the head not being in its normal position, shoulder asymmetry, valgus in the knees, scoliosis in the spine, thoracic kyphosis, and lumbar lordosis deformities.

Epidemiological studies investigating the relationship between visual sensory input and scoliosis show that the incidence of scoliosis is higher in the visually impaired population.^{3,8} Catanzariti and Thevenon et al.³ reported five times more scoliosis cases in people with visual impairment compared to the control group. Grivas et al.⁸ found the incidence of scoliotic deformity to be 42% in visually impaired women. In order to determine the relationship between the direction of curvature and the volume of the eye muscles and visual field in individuals with scoliosis, the AIS group included in our study was formed only from individuals with right thoracic scoliosis. To minimize the effect of gender and hormonal factors on the data in the study, patient and asymptomatic groups were formed exclusively from women. The study found that the deviation in the visual field was higher in individuals with AIS than in the control group. Additionally, according to the study data, asymmetry was observed in the right and left visual field tests in individuals with AIS. This result clearly reveals the relationship between scoliosis and the sense of sight. Information from the vestibular, ocular, and proprioceptive organs is needed to maintain proper posture. The most important of these senses is the sense of sight, which encodes and processes information from all other senses. Therefore, children are more dependent on visual information in the first days of life than on somatosensory and vestibular information.¹⁶ In a study, it was reported that temporal and spatial information were processed more slowly in visually impaired children and remained at a lower level than in children with normal motor development.²⁰ Studies show that visually impaired children may experience more postural discomfort than individuals with only head and cervical spine alignment problems.^{21,22}

Recent studies show that children with normal development usually exhibit postural changes during the growth period, but children with visual impairment may experience postural deformities at any time.^{19,21,22} Therefore, it should not be overlooked that knowing the visual fields and morphology of eye-moving muscles of individuals with AIS and revealing their possible relationship with postural changes may be of critical importance in the diagnosis and treatment of the musculoskeletal system. It is important to examine the anatomy of musculoskeletal structures to have information about the stability limits of in-

dividuals.²³ Therefore, in our study, we calculated the volumes of MR and LR muscles of individuals with AIS. Our data revealed that the MR muscle of individuals with AIS had a smaller volume than the control group, and there was asymmetry in right-left MR muscle sizes. Based on these data, it is evident that muscle imbalance due to spinal curvature in individuals with scoliosis is not limited to the spine but can also be seen in the muscles responsible for the movement of the eye. We believe that asymmetry in the muscles will affect the visual field and contribute to the development or progression of existing scoliosis.

Limitations: The first limitation is that the sample size is small. Second, the orientation of muscle fibers correlates with skeletal morphology, but muscle fiber orientation was not examined in this study. Additionally, it was not specified how long the individuals with AIS included in the study were followed for treatment after diagnosis. Third, the calculation of the volume of eye muscles other than MR and LR eye muscles could not be properly done based on the MR images we have. Only the volumes of the MR and LR muscles were examined among the muscles responsible for eye movement. As other muscles could not be evaluated, it is unknown how these muscles differ between groups.

CONCLUSION

A significant asymmetry in the volume of the MR muscle was identified in individuals with AIS. Additionally, it was observed that their muscle volumes were smaller compared to asymptomatic individuals. Alongside changes in the biomechanics of the spine, anatomical, biomechanical, and kinesiological changes were observed in the muscle components of the eye. However, it remains unknown whether AIS causes visual impairment or if visual impairment causes AIS. Further comprehensive studies are required to investigate this relationship.

Peer-review: Externally peer-reviewed.

Ethics Committee Approval: The Kayseri City Training and Research Hospital Clinical Research Ethics Committee granted approval for this study (date: 02.12.2021, number: 539).

Informed Consent: Written informed consent was obtained from patients who participated in this study.

Author Contributions: Concept – SB, İU, AP; Design – SB, İU, AP, EB, EU; Supervision – İU, YE, EU; Resource – SB, İU, AP, EB, MA, EK, EU; Materials – AP, EK, NK, HY; Data Collection and/or Processing – SB, AP, NK, EB, MA; Analysis and/or Interpretation – AP, NK, HY, TS, EK, YE; Literature Search – SA, İU, AP, EB, MA, NK; Writing – SB, İU, AP; Critical Reviews – YE, MA, EU.

Conflict of Interest: The authors have no conflict of interest to declare.

Financial Disclosure: The authors declared that this study has received no financial support.

REFERENCES

1. Le Berre M, Guyot MA, Agnani O, Bourdeauducq I, Versyp MC, Donze C, et al. Clinical balance tests, proprioceptive system and adolescent idiopathic scoliosis. *Eur Spine J* 2017; 26(6): 1638–44. [\[CrossRef\]](#)
2. Burwell RG. Aetiology of idiopathic scoliosis: current concepts. *Pediatr Rehabil* 2003; 6(3-4): 137–70. [\[CrossRef\]](#)
3. Catanzariti JF, Salomez E, Bruandet JM, Thevenon A. Visual deficiency and scoliosis. *Spine (Phila Pa 1976)* 2001; 26(1): 48–52. [\[CrossRef\]](#)
4. Şahin F, Urak Ö, Akkaya N. Evaluation of balance in young adults with idiopathic scoliosis. *Turk J Phys Med Rehabil* 2019; 65(3): 236–43. [\[CrossRef\]](#)
5. Kwon YH, Choi YW, Nam SH, Lee MH. The influence of time of day on static and dynamic postural control in normal adults. *J Phys Ther Sci* 2014; 26(3): 409–12. [\[CrossRef\]](#)
6. Lee DN, Lishman J. Visual proprioceptive control of stance. *J Human Movement Stu* 1975; 1(2): 87–95.
7. Payas A, Batin S, Kurtoğlu E, Arik M, Seber T, Uçar İ, et al. Is the integration problem in the sensorimotor system the cause of adolescent idiopathic scoliosis? *J Pediatr Orthop* 2023; 43(2): e111–9. [\[CrossRef\]](#)
8. Grivas TB, Savvidou OD, Vasiliadis E, Psarakis S, Koufopoulos G. Prevalence of scoliosis in women with visual deficiency. *Stud Health Technol Inform* 2006; 123: 52–6.
9. Howard C, Rowe FJ. Adaptation to poststroke visual field loss: A systematic review. *Brain Behav* 2018; 8(8): e01041.
10. Uçar İ, Batin S, Arik M, Payas A, Kurtoğlu E, Karartı C, et al. Is scoliosis related to mastication muscle asymmetry and temporomandibular disorders? A cross-sectional study. *Musculoskelet Sci Pract* 2022; 58: 102533. [\[CrossRef\]](#)
11. Weinstein SL, Dolan LA, Cheng JC, Danielsson A, Morcuende JA. Adolescent idiopathic scoliosis. *Lancet* 2008; 371(9623): 1527–37. [\[CrossRef\]](#)
12. de Sèze M, Cugy E. Pathogenesis of idiopathic scoliosis: A review. *Ann Phys Rehabil Med* 2012; 55(2): 128–38. [\[CrossRef\]](#)
13. Nakashima A, Yamada T, Nakano H, Sugiyama G, Sugi T, Kamata Y, et al. Jaw asymmetry may cause bad posture of the head and the spine-A preliminary study. *J Oral & Maxillofacial Surg, Med, and Pathology* 2018; 30(3): 242–6. [\[CrossRef\]](#)
14. Dufvenberg M, Adeyemi F, Rajendran I, Öberg B, Abbott A. Does postural stability differ between adolescents with idiopathic scoliosis and typically developed? A systematic literature review and meta-analysis. *Scoliosis Spinal Disord* 2018; 13: 19. [\[CrossRef\]](#)
15. Massion J, Woollacott MH. Posture and equilibrium. In: Balance, Posture and Gait. Bronstein AM, Brandt T, Woollacott M, editors. London: Arnold; 1996.pp.1–18.
16. van Beers RJ, Sittig AC, Gon JJ. Integration of proprioceptive and visual position-information: An experimentally supported model. *J Neurophysiol* 1999; 81(3): 1355–64.
17. Graziano MS, Cooke DF, Taylor CS. Coding the location of the arm by sight. *Science* 2000; 290(5497): 1782–6. [\[CrossRef\]](#)
18. Sarlegna FR, Sainburg RL. The roles of vision and proprioception in the planning of reaching movements. *Adv Exp Med Biol* 2009; 629: 317–35. [\[CrossRef\]](#)
19. de Pádua M, Sauer JF, João SMA. Quantitative postural analysis of children with congenital visual impairment. *J Manipulative Physiol Ther* 2018; 41(1): 62–70. [\[CrossRef\]](#)
20. Aulisa L, Bertolini C, Piantelli S, Piazzini DB. Axial deviations of the spine in blind children. *Ital J Orthop Traumatol* 1986; 12(1): 85–92.
21. Watson AW, Mac Donncha C. A reliable technique for the assessment of posture: assessment criteria for aspects of posture. *J Sports Med Phys Fitness* 2000; 40(3): 260–70.
22. Iunes DH, Castro FA, Salgado HS, Moura IC, Oliveira AS, Bevilacqua-Grossi D. Intra and inter-examiner reliability and method repeatability of postural evaluation via photogrammetry. [Article in Portuguese]. *Braz J Phys Ther* (Print) 2005; 9(3): 327–34.
23. Uçar İ, Karartı C, Cüce İ, Veziroğlu E, Özüdoğru A, Koçak FA, et al. The relationship between muscle size, obesity, body fat ratio, pain and disability in individuals with and without nonspecific low back pain. *Clin Anat* 2021; 34(8): 1201–7.