



Posterior cruciate ligament reconstruction via tibial inlay technique in multiligament knee injuries

Sinan ZEHİR¹, Nurzat ELMALI², Ercan ŞAHİN³, Murat ÇALBIYIK¹, Mustafa KARAKAPLAN⁴, Zeki TAŞDEMİR²

¹Hitit University Faculty of Medicine, Department of Orthopaedics and Traumatology, Çorum, Turkey

²Bezmi Alem Vakıf University, Department of Orthopaedics and Traumatology, İstanbul, Turkey

³Bülent Ecevit University Faculty of Medicine, Department of Orthopaedics and Traumatology, Zonguldak, Turkey

⁴İnönü University Faculty of Medicine, Department of Orthopaedics and Traumatology, Malatya, Turkey

Objective: The aim of this study is to report our institution's experience regarding the use of open tibial inlay technique in patients undergoing single-stage combined posterior cruciate ligament (PCL) reconstruction.

Methods: Records of 17 patients who underwent PCL reconstruction with tibial inlay technique were retrospectively reviewed. Patients with ipsilateral femoral or tibial osteochondral avulsion fractures or ipsilateral concomitant tibia and femur shaft fractures were excluded. Out of these 17 patients, six cases underwent anterior cruciate ligament (ACL) + PCL reconstruction, nine cases underwent ACL + PCL + posterolateral corner reconstruction, one case underwent ACL + PCL + MCL reconstruction and one case underwent ACL + PCL + posterolateral corner + MCL reconstruction. Mean follow-up was 14.27±6.77 (range: 6–30) months.

Results: In preoperative assessments, all patients had 3+ posterior laxity in posterior drawer test; at final follow-up, 6 patients had 0 laxity, 7 patients had 1+ laxity, and 4 patients had 2+ laxity ($p < 0.001$). International Knee Documentation Committee (IKDC) objective evaluation showed severe disability in all patients preoperatively, whereas 5 knees were grade A, 8 knees were grade B, 3 knees were grade C, and 1 knee was grade D at final follow-up. Mean IKDC subjective score was 75.22±7.53 at final follow-up. Postoperatively, mean side-to-side difference in KT-1000 arthrometer measurement was 2.45±1.80 mm. At final follow-up, mean range of motion (ROM) was 0° on extension and 123.56±6.31° on flexion.

Conclusion: Open tibial inlay approach is beneficial during PCL reconstruction. Further study is warranted to establish its effectiveness on functional outcomes and prevention of complications.

Keywords: Knee ligament injury; posterior cruciate ligament; tibial inlay.

Level of Evidence: Level IV Therapeutic Study

Annual incidence of knee ligament injuries is reported to be 60.9 per 100,000 people, with posterior cruciate ligament (PCL) injuries being far less common than anterior

cruciate ligament (ACL) injuries.^[1,2] The PCL is referred to as the “central pivot” of all of all other ligaments,^[3] and surgical reconstruction for PCL injuries remains con-

Correspondence: Sinan Zehir, MD. Hitit Üniversitesi Tıp Fakültesi, Ortopedi ve Travmatoloji Anabilim Dalı, Bahçelievler Mah., Çamlık Cad., No: 2, 19030 Çorum, Turkey.

Tel: +90 364 – 222 11 00 e-mail: sinanzehir@yahoo.com


Submitted: November 24, 2014 **Accepted:** March 28, 2015

©2015 Turkish Association of Orthopaedics and Traumatology

Available online at
www.aott.org.tr

doi: 10.3944/AOTT.2015.14.0443

QR (Quick Response) Code



troversial. It was reported that patients with isolated PCL tears may experience functional improvement and achieve recovery after completing physical rehabilitation without surgery.^[4] Although surgery for ACL injuries is undertaken to avoid future complications including further disability and future osteoarthritis, such benefit has not yet been established in patients undergoing surgery for isolated PCL reconstruction.^[5] Nevertheless, there have been several studies in the last decade reporting improved functional outcome following isolated PCL reconstruction, indicating a potential benefit of surgery in certain situations.^[6]

There are various surgical reconstruction methods for PCL injury, including single- or double-bundle graft reconstruction, which may be performed through arthroscopic, transtibial, or tibial inlay approaches. Although arthroscopic PCL reconstruction was shown to be of use in creating a near-anatomic tunnel,^[7] the technique is quite difficult to perform. The transtibial technique provides adequate posterior stability, and as a result, it is the most commonly used technique for PCL reconstruction. However, the most prominent disadvantage of this technique is the “killer turn” effect, the sharp turn of the graft as it leaves the tibial tunnel, resulting in long-term graft attenuation.^[8] The tibial inlay technique was developed to overcome such limitations of the transtibial technique.

In this study, we report our institution’s experience using the open tibial inlay technique in patients undergoing isolated or combined multiligament PCL reconstruction with a single-bundle Achilles allograft for treatment of isolated or multiligament knee injuries.

Patients and methods

This retrospective cohort study was conducted on patients undergoing PCL reconstruction using Achilles tendon allograft with tibial inlay technique between January 2009 and April 2013 in 2 distinct institutions. Signed informed consent was obtained from each patient. Search of the hospitals’ databases revealed that a total of 17 patients (13 males, 4 females; mean age: 29.2 years) were available for the study. All operations were performed by one of 2 surgeons who had experience in knee reconstruction surgery. Inclusion criteria were presence of isolated PCL injury or combined knee ligament injuries involving PCL and anterior and/or medial collateral ligaments and posterolateral corner (PLC) structures requiring surgical reconstruction. Patients with ipsilateral femoral or tibial osteochondral avulsion fractures or ipsilateral concomitant tibia and femur shaft fractures were excluded. Preoperative and postoperative

patient counseling charts, physical examination records, and anteroposterior radiographs (with knee at 90° flexion) were investigated (Figure 1). The International Knee Documentation Committee (IKDC) scale was used for evaluation of outcomes. KT-1000 arthrometer was used for documentation of postoperative laxity. The device was calibrated to neutral position by performing several anterior and posterior translations to the involved knee and then to the intact knee with the knee at 25° flexion. Side-to-side differences were calculated at maximal manual force. Clinical diagnosis of PCL injury was made upon posterior drawer testing, which was repeated at follow-up. Varus stress test was used to assess lateral laxity at 0° and 30° of flexion (graded as 0, 1, 2, or 3).

All operations were performed under general anesthesia. The patients were laid supine, and a tourniquet was applied to the involved leg.^[9] Diagnostic arthroscopy was performed to assess for any meniscal or cartilage lesions, which were treated as necessary. Remnants of torn ligaments were removed, and notchplasty was performed to eliminate possible graft impingement and to create adequate space for ligament reconstruction. The tendon

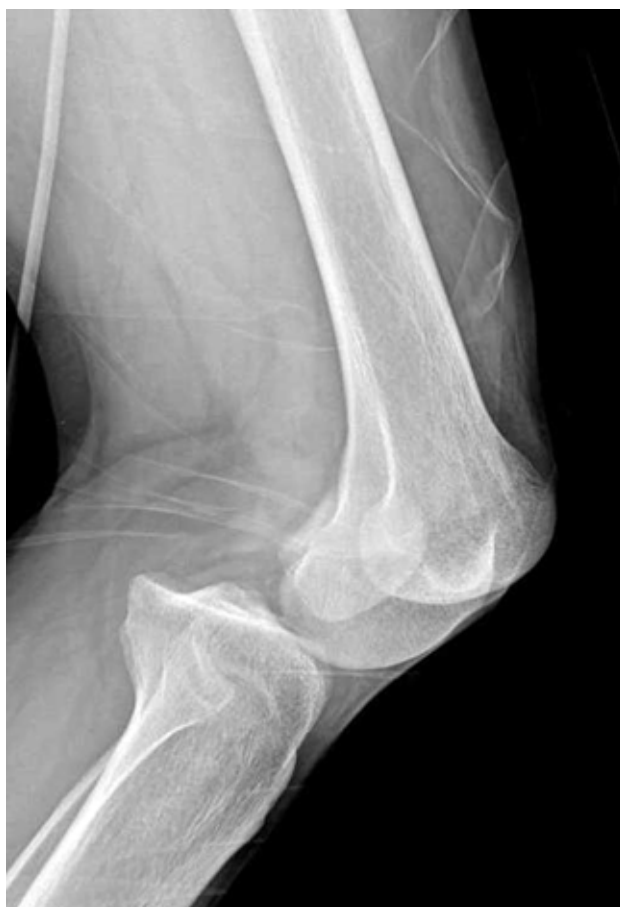

Fig. 1. Lateral radiograph of a patient with ACL/PCL/PLC injuries.

end of the Achilles allograft was sutured in whip stitch fashion. An autogenous quadrupled hamstring graft was harvested in patients receiving simultaneous ACL reconstruction. Hamstring grafts were prepared. The PCL femoral tunnel was created as previously described.^[10] A femoral tunnel 10 mm in diameter was reamed, with its center being 7 mm proximal to the margin of the medial epicondyle. The patient was then positioned prone to access the posterior knee.

A modified posteromedial exposure was performed as previously described.^[11] The tibial inlay site was prepared. The capsule was incised, and a groove was created over the PCL footprint to implant the inlay graft. The bone plug of the inlay graft was implanted and firmly secured with 3.5-mm cancellous screw and washer. The wire loop that was placed into the joint earlier was retrieved and used to shuttle the sutures placed in the tendinous portion of the graft through the femoral tunnel. The tendinous part of the graft was pulled into the femoral tunnel (Figure 2). The patient was repositioned from prone to supine, adequate placement and passage of the graft were confirmed arthroscopically, and the graft was fixed with an absorbable interference screw.

In patients undergoing combined ACL reconstruction, the tibial tunnel was created next through the anteromedial portal, and the ACL femoral tunnel was created via the tibial tunnel. The ACL graft was passed through the tibial tunnel and introduced into the femoral tunnel. Femoral fixation was performed with an absorbable interference screw. When indicated, PLC reconstruction was performed using a modified fibular tunnel technique, as described by Jung et al.^[12] A tibialis anterior allograft was used for PLC reconstruction. In 4 cases with combined PCL/PLC injuries, anatomical reconstruction was performed using the technique described by LaPrade et al.^[13] In these patients, there was co-existence of PLC and lateral collateral ligament (LCL) instability, and isolated LCL reconstruction was avoided due to the presence of rotator laxity and varus laxity on clinical examination. In 2 patients with acute MCL injury, the ligament was reconstructed primarily.

All involved extremities were immobilized at full extension in long leg casts for 4 weeks. Straight leg raising exercises were started on the first postoperative day, and partial weight-bearing was allowed. The casts were removed, and progressive range of motion (ROM) exercises were begun. Full weight-bearing was allowed at the third postoperative month. In order to protect the reconstructed PCL, hamstring exercises were not allowed, nor were patients allowed to perform sports activities before the twelfth postoperative month. Two patients with

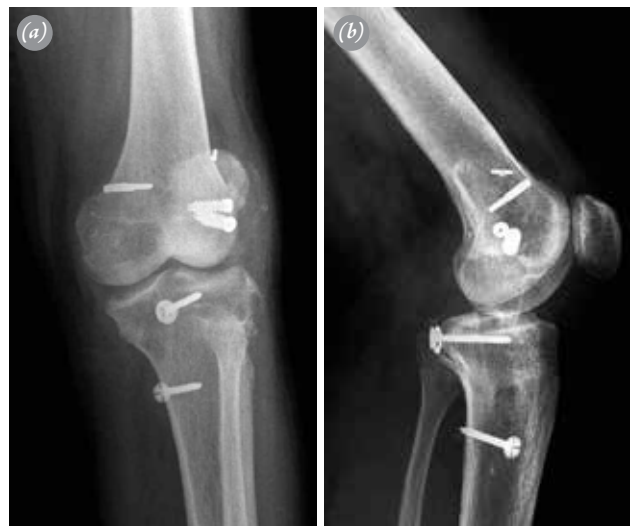

Fig. 2. (a) Anteroposterior, (b) Lateral radiographs demonstrating ACL/PCL/PLC reconstruction (postoperative).

femoral shaft fractures had severe instability and received spanning-joint external fixation for 4 weeks. These patients followed a standard rehabilitation program thereafter.

All statistical analyses were performed using SPSS 16.0 (SPSS Inc., Chicago, IL, USA) software. Continuous variables were defined by mean \pm standard deviations, and categorical data were expressed with numbers and percentages in brackets. Related sampled Wilcoxon signed-rank test was used to compare preoperative and postoperative parameters.

Results

Patient characteristics and the surgical procedures performed on each patient are given in Table 1. Patients with gross instability, vascular injury, ipsilateral femur fracture, or knee dislocation were treated with spanning-joint external fixation for 3 to 4 weeks after the operation. In 2 patients, surgery was performed for chronic sports related injury; operations were performed at 8 months and 18 months after injury, respectively. In the remaining patients, operations were performed within 4 weeks after injury. The mechanism of injury was non-sports related trauma in 11 patients and sports related trauma in 6 patients.

Mean time from injury to operation was 2.94 ± 0.65 weeks. Ipsilateral femoral shaft fracture was present in 2 patients, and ipsilateral trochanteric fracture was present in 1 patient. One patient had right side ankle fracture and underwent fixation. Four patients with meniscal injuries received all-inside meniscal repair, whereas 2 patients received partial meniscectomy. Two patients had

Table 1. Baseline patient characteristics and concomitant procedures performed on each patient.

No	Age	Sex	Mechanism of injury	Preop IKDC	Time to operation	Preop PDT	Knee dislocation	Reconstruction	Postop IKDC	Follow-up (months)
1	40	Male	Out-vehicle accident	57	3 weeks	+++	+	Left ACL+PCL+PLC	89	16
2	34	Female	Out-vehicle accident	48	4 weeks	+++	+	Right ACL+PCL+PLC+MCL	87	12
3	21	Female	Fall	38	3 weeks	+++		Left ACL+PCL	84	28
4	27	Male	Sports injury	49	1.5 years	+++		Right ACL+PCL	62	10
5	24	Male	Sports injury	45	8 months	+++		Right ACL+PCL	90	14
6	25	Female	In-vehicle accident	41	4 weeks	+++	+	Left ACL+PCL+PLC	74	10
7	33	Male	Out-vehicle accident	45	4 weeks	+++	+	Left ACL+PCL+PLC	87	6
8	27	Male	Out-vehicle accident	33.5	2 weeks	++++		Left ACL+PCL+PLC	90.4	21
9	17	Male	Out-vehicle accident	15.7	4 weeks	+++		Left ACL+PCL+PLC	87.5	12
10	31	Male	Fall	25.4	4 weeks	+++	+	Right ACL+PCL+PLC	85.2	11
11	34	Male	Fall	37.9	3 weeks	+++		Left ACL+PCL	93.1	14
12	40	Male	Out-vehicle accident	20.7	2 weeks	+++		Left ACL+PCL+MCL	80.5	9
13	24	Male	Out-vehicle accident	14.6	4 weeks	+++	+	Right ACL+PCL+PLC	67	30
14	42	Male	Sports injury	43.6	3 weeks	++++		Right ACL+PCL	92.3	21
15	29	Male	Sports injury	37.8	4 weeks	++++		Right ACL+PCL	84.8	8
16	33	Male	Out-vehicle accident	26.1	4 weeks	+++		Left ACL+PCL+PLC	73.1	11
17	34	Male	Fall	41.2	3 weeks	+++		Left ACL+PCL	87.6	13

Preop: Preoperative; Postop: Postoperative; IKDC: International Knee Documentation Committee; PDT: Posterior drawer test; ACL: Anterior cruciate ligament; PCL: Posterior cruciate ligament; PLC: Posterolateral corner; MCL: Medial collateral ligament.

concomitant popliteal artery injury, which was primarily repaired intraoperatively by a vascular surgeon.

An autologous quadrupled hamstring graft was used for ACL reconstruction, and a tibialis anterior allograft was used for PLC reconstruction in all patients. Mean follow up was 14.27 ± 6.77 (range: 6–30) months.

In preoperative assessments, all patients had 3+ posterior laxity in posterior drawer test; at final follow-up, 6 patients had 0 laxity, 7 patients had 1+ laxity, and 4 patients had 2+ laxity ($p < 0.001$). IKDC objective evaluation showed severe disability in all patients preoperatively, whereas 5 knees were grade A, 8 knees were grade B, 3 knees were grade C, and 1 knee was grade D at final follow-up. Mean IKDC subjective score was 75.22 ± 7.53 at final follow-up. Postoperative at 3rd week, mean side-to-side difference in KT-1000 arthrometer was 2.45 ± 1.80 mm.

At final follow-up, mean ROM was 0° on extension and $115.29^\circ \pm 19.64^\circ$ (range: 70° – 135°) on flexion. Clinical examination with varus stress testing comparing the injured and contralateral knee in the patients showed no side to-side difference in lateral laxity (grade 0) at 0° or 30° in 13 patients and grade 1 laxity (1–5 mm) at 30° in 4 patients. Anteroposterior radiographs of the patients were taken and moderate (Kellgren-Lawrence grade 3) arthritic changes were seen in 2 patients who underwent ACL+PCL+PLC reconstruction. All remaining patients had Kellgren-Lawrence grade 1 to 2 arthritic changes.

Complications occurred in 3 patients. One patient (Patient 17) had superficial wound infection and recovered with wound care and appropriate antibiotics. Another patient (Patient 5) presented with deep wound infection 3 weeks postoperatively. He underwent a revision surgery, and the infected ACL implants were removed. One of the patient who had vascular injury at the time of surgery developed foot drop and was assigned to a specific rehabilitation protocol.

Discussion

This study was based on our institutional experience regarding the use of open tibial inlay

technique for PCL reconstruction, and the results demonstrate that this technique provides satisfactory improvement in posterior laxity and subjective complaints, even when combined with multiligament procedures. Mechanism of injury was not sports-related in 11 of 17 patients, and 4 of these had associated fractures at the affected site that occurred due to high-energy vehicle accident. A great majority of our patients received simultaneous ACL reconstruction, and an additional procedure for reconstruction of posterior corner structures was required in a lesser majority of them. Thus, surgical reconstruction for PLC appears necessary in patients requiring complex multiligament procedures, leaving the surgeon to face a more complicated situation than that seen in isolated ACL injuries.

The technique we used for PCL reconstruction was similar to that which was described previously by Cooper et al.,^[14] consisting of single-bundle reconstruction using an Achilles allograft via open inlay approach, devised from an earlier description by Burks et al.^[11] However, Cooper et al.^[14] used the technique with bone-patellar tendon-bone graft in 44 patients; the overall success rate was relatively high, leading the authors to emphasize the usefulness of tibial inlay technique in revision surgery. Use of the bone plug of the Achilles tendon allograft for fixation of the graft through tibial inlay approach is quite advantageous, as we witnessed in the present study, and biomechanical stability of the graft was confirmed previously.^[15] However, it was also shown that Achilles tendon allografts were more prone than quadriceps tendons to cause bone avulsion.^[16]

Numerous studies have sought to determine whether reconstruction for isolated PCL injury is necessary,^[3,17-19] while others have investigated PCL reconstruction in combination with multiligament procedures.^[14,19-21] One study reported that after a minimum follow-up of 10 years, mean IKDC score of patients treated non-operatively was 73.4 ± 21.7 , and approximately 90% of patients did not have osteoarthritis.^[4] Moreover, in the study by Cooper et al.,^[14] in which 85% of patients underwent combined ligament reconstructions, the authors reported that combined reconstructions tended to be more stable than isolated reconstruction.

In an earlier study, Stannard et al.^[20] utilized a staged procedure, performing ACL reconstruction 8 weeks after PCL reconstruction in order to begin PCL rehabilitation earlier. Strobel et al.^[22] reported that arthroscopic transtibial PCL reconstruction provided considerable improvement in knee function when combined with single-stage ACL and PLC reconstruction. Similar to ours, these 2 studies included patients undergoing PLC

reconstruction and reported promising results. We are of the opinion that using the open tibial inlay technique increases surgeon confidence during final fixation and tensioning of the grafts after completion of multiligament reconstructions.

In a 2010 review, Papalia et al.^[23] included 10 studies (5 retrospective and 5 prospective cohorts) on tibial inlay technique for PCL reconstruction. In this review, scientific validity of the studies was found acceptable in terms of methodological quality and the rate of success reported by IKDC form and Lysholm scale. Orthopädische Arbeitsgruppe Knie (OAK) score ranged from 73.7% to 100% in a total of 255 patients. It may be inferred from this report that PCL reconstruction via tibial inlay approach is usually performed in combination with other procedures. However, while recent studies have focused on the issue, it remains unclear whether single-bundle tibial inlay reconstruction technique should be modified as the double-bundle technique. Shon et al.^[10] used single-bundle tibial inlay reconstruction in 14 patients and double-bundle reconstruction in 16 patients and concluded that it is unnecessary to perform a more demanding double-bundle reconstruction. In contrast, Kim et al.^[24] compared functional results among patients receiving single-bundle transtibial technique ($n=8$), arthroscopic inlay single-bundle technique ($n=11$), and arthroscopic inlay double-bundle technique ($n=10$) and reported that arthroscopic inlay double-bundle technique produced better functional outcomes than the other 2 techniques. Since the majority of our patients required combined reconstructions, we did not attempt double-bundle tibial inlay reconstruction, as the technique would likely increase the difficulty of an already difficult operation.

Eliminating the “killer turn” effect and providing construction of a near-anatomic graft placement, open tibial inlay technique has become an alternative to arthroscopic transtibial PCL reconstruction. However whether these advantages are linked to better outcomes is still controversial, since both biomechanical studies and clinical studies have failed to clearly demonstrate the superiority of the technique in this regard.^[25] MacGillivray et al.^[26] compared the outcomes of 13 patients who underwent arthroscopic transtibial PCL reconstruction with 7 patients undergoing tibial inlay reconstruction for isolated PCL injury and concluded that neither technique restored anteroposterior stability when single-bundle reconstruction was performed. In another comparative study on 39 patients, Seon et al.^[27] suggested that both the transtibial technique and tibial inlay technique provided satisfactory improvement

in isolated PCL in Lysholm knee scores and posterior drawer test, and mean side-to-side differences were similarly improved in both groups, indicating that both techniques were effective in terms of functional outcomes for isolated PCL reconstruction. Similar to the present study, these 2 comparative studies were retrospective in design and also limited in quality by the low number of patients. We performed only 2 isolated PCL reconstructions in this series; therefore, we cannot draw a clear conclusion regarding its superiority over arthroscopic repair. However, we believe that we gained the advantage of obtaining good visualization of the tibial attachment site of the PCL, which would be more difficult for the surgeon during arthroscopic repair.

Our patients were allowed to begin ROM exercises after being immobilized in long leg casts for 4 weeks to avoid graft failure. In Strobel et al.'s series,^[22] patients were allowed to begin ROM exercises in the second postoperative week using a posterior tibial support brace, which they were able to successfully perform. Similarly, in Cooper et al.'s series,^[14] all but 4 knees were immobilized with a hinged knee brace locked in 0°, and the brace was unlocked after 2 weeks to allow for ROM exercises. These authors reported that aggressive ROM exercises were associated with PCL surgery failure. We achieved satisfactory ROM levels at final follow-up, leading us to conclude that preservation of reconstructed ligaments should be ensured to allow for progressive ROM exercises.

The technique we performed necessitates positioning the patient supine at the beginning of surgery, changing to prone position during tibial inlay exposure, and positioning supine again at the final stage. This technique is time-consuming but allows satisfactory direct vision to the tibial inlay area. There is no standard for positioning of the patient during PCL reconstruction via tibial inlay approach, especially when multiligament reconstruction is performed. Stannard et al.^[20] provided no information about positioning the patient. However, others achieved adequate vision without repositioning the patient. Cooper et al.^[14] reported that they used the lateral decubitus position earlier in their series, whereas they continued with supine position in later cases. Strobel et al.^[22] reported that supine positioning was used during PCL reconstructions where most of their patients underwent combined multiligament reconstructions.

This study had several limitations including retrospective design, small sample size, and lack of control group. Based on our observations, we conclude that PCL reconstruction using open tibial inlay technique is an effective method to improve knee function. The technique provides optimal visualization of posterior at-

tachment of PCL and enhances the surgeon's room for manipulation, which is a major concern for single-stage procedures that entail reconstruction of multiligament injuries of the knee.

Conflicts of Interest: No conflicts declared.

References

1. Parkkari J, Pasanen K, Mattila VM, Kannus P, Rimpelä A. The risk for a cruciate ligament injury of the knee in adolescents and young adults: a population-based cohort study of 46 500 people with a 9 year follow-up. *Br J Sports Med* 2008;42:422-6.
2. Swenson DM, Collins CL, Best TM, Flanigan DC, Fields SK, Comstock RD. Epidemiology of knee injuries among U.S. high school athletes, 2005/2006-2010/2011. *Med Sci Sports Exerc* 2013;45:462-9.
3. Levy BA, Fanelli GC, Whelan DB, Stannard JP, MacDonald PA, Boyd JL, et al. Controversies in the treatment of knee dislocations and multiligament reconstruction. *J Am Acad Orthop Surg* 2009;17:197-206.
4. Shelbourne KD, Clark M, Gray T. Minimum 10-year follow-up of patients after an acute, isolated posterior cruciate ligament injury treated nonoperatively. *Am J Sports Med* 2013;41:1526-33.
5. Shelbourne KD, Gray T. Minimum 10-year results after anterior cruciate ligament reconstruction: how the loss of normal knee motion compounds other factors related to the development of osteoarthritis after surgery. *Am J Sports Med* 2009;37:471-80.
6. Kim YM, Lee CA, Matava MJ. Clinical results of arthroscopic single-bundle transtibial posterior cruciate ligament reconstruction: a systematic review. *Am J Sports Med* 2011;39:425-34.
7. Gancel E, Magnussen RA, Lustig S, Demey G, Neyret P, Servien E. Tunnel position following posterior cruciate ligament reconstruction: an in vivo computed tomography analysis. *Knee* 2012;19:450-4.
8. Voos JE, Mauro CS, Wente T, Warren RF, Wickiewicz TL. Posterior cruciate ligament: anatomy, biomechanics, and outcomes. *Am J Sports Med* 2012;40:222-31.
9. McAllister DR, Hussain SM. Tibial inlay posterior cruciate ligament reconstruction: surgical technique and results. *Sports Med Arthrosc* 2010;18:249-53.
10. Shon OJ, Lee DC, Park CH, Kim WH, Jung KA. A comparison of arthroscopically assisted single and double bundle tibial inlay reconstruction for isolated posterior cruciate ligament injury. *Clin Orthop Surg* 2010;2:76-84.
11. Burks RT, Schaffer JJ. A simplified approach to the tibial attachment of the posterior cruciate ligament. *Clin Orthop Relat Res* 1990;254:216-9.
12. Jung YB, Jung HJ, Kim SJ, Park SJ, Song KS, Lee YS, et al. Posterolateral corner reconstruction for posterolateral

- rotatory instability combined with posterior cruciate ligament injuries: comparison between fibular tunnel and tibial tunnel techniques. *Knee Surg Sports Traumatol Arthrosc* 2008;16:239–48.
13. LaPrade RF, Johansen S, Wentorf FA, Engebretsen L, Esterberg JL, Tso A. An analysis of an anatomical posterolateral knee reconstruction: an in vitro biomechanical study and development of a surgical technique. *Am J Sports Med* 2004;32:1405–14.
 14. Cooper DE, Stewart D. Posterior cruciate ligament reconstruction using single-bundle patella tendon graft with tibial inlay fixation: 2- to 10-year follow-up. *Am J Sports Med* 2004;32:346–60.
 15. Ruberte Thiele RA, Campbell RB, Amendola A, Sekiya JK. Biomechanical comparison of figure-of-8 versus cylindrical tibial inlay constructs for arthroscopic posterior cruciate ligament reconstruction. *Arthroscopy* 2010;26:977–83.
 16. Mabe I, Hunter S. Quadriceps tendon allografts as an alternative to Achilles tendon allografts: a biomechanical comparison. *Cell Tissue Bank* 2014;15:523–9.
 17. Wajsfisz A, Christel P, Djian P. Does reconstruction of isolated chronic posterior cruciate ligament injuries restore normal knee function? *Orthop Traumatol Surg Res* 2010;96:388–93.
 18. Gauffin H, Rockborn P. Knee dislocations: is reconstruction of the posterior cruciate ligament crucial? *Eur J Orthop Surg Traumatol* 2014;24:371,7.
 19. Difelice GS, Lissy M, Haynes P. Surgical technique: when to arthroscopically repair the torn posterior cruciate ligament. *Clin Orthop Relat Res* 2012;470:861–8.
 20. Stannard JP, Riley RS, Sheils TM, McGwin G Jr, Volgas DA. Anatomic reconstruction of the posterior cruciate ligament after multiligament knee injuries. A combination of the tibial-inlay and two-femoral-tunnel techniques. *Am J Sports Med* 2003;31:196–202.
 21. Chuang TY, Ho WP, Hsieh PH, Yu SW, Chen YJ, Chen CH. One-stage posterior cruciate ligament inlay reconstruction combining anterior cruciate ligament reconstruction following knee dislocation. *Arthroscopy* 2006;22:339.e1–7.
 22. Strobel MJ, Schulz MS, Petersen WJ, Eichhorn HJ. Combined anterior cruciate ligament, posterior cruciate ligament, and posterolateral corner reconstruction with autogenous hamstring grafts in chronic instabilities. *Arthroscopy* 2006;22:182–92.
 23. Papalia R, Osti L, Del Buono A, Denaro V, Maffulli N. Tibial inlay for posterior cruciate ligament reconstruction: a systematic review. *Knee* 2010;17:2649.
 24. Kim SJ, Kim SH, Kim SG, Kung YP. Comparison of the clinical results of three posterior cruciate ligament reconstruction techniques: surgical technique. *J Bone Joint Surg Am* 2010;92 Suppl 1 Pt 2:145–57.
 25. Panchal HB, Sekiya JK. Open tibial inlay versus arthroscopic transtibial posterior cruciate ligament reconstructions. *Arthroscopy* 2011;27:1289–95.
 26. MacGillivray JD, Stein BE, Park M, Allen AA, Wickiewicz TL, Warren RF. Comparison of tibial inlay versus transtibial techniques for isolated posterior cruciate ligament reconstruction: minimum 2-year follow-up. *Arthroscopy* 2006;22:320–8.
 27. Seon JK, Song EK. Reconstruction of isolated posterior cruciate ligament injuries: a clinical comparison of the transtibial and tibial inlay techniques. *Arthroscopy* 2006;22:27–32.