

# Tümesan Anesteziyle Ekstra-anatomik By-pass: Olgu Sunumu

## Extra-anatomic By-pass with Tumescent Anesthesia: A case Report

**Seyhan Yılmaz<sup>1</sup>, Özgür Barış<sup>1</sup>, Adnan Yalçınkaya<sup>2</sup>, Behice Kaniye Yılmaz<sup>3</sup>**

1SBÜ Derince Eğitim ve Araştırma Hastanesi, Kalp Damar Cerrahisi Kliniği, Kocaeli, Türkiye

2Çorum Eğitim ve Araştırma Hastanesi, Kalp Damar Cerrahisi Kliniği, Çorum, Türkiye

3Haseki Eğitim ve Araştırma Hastanesi, Radyoloji Kliniği, İstanbul, Türkiye

### ÖZET

Periferik arteriyel dolaşım bozuklukları günümüzde önemli bir morbidite ve mortalite nedenidir. Ekstra-anatomik baypas operasyonları ekstremiteler kurtarılması için yüksek riskli hasta gruplarında tercih edilebilen alternatif yöntemlerdir. Bu olgu sunumunda, ileri evre Kronik obstruktif akciğer hastalığı ve istirahat dispnesi, geçirilmiş torakal aort operasyonu ve geçirilmiş lomber disk hernisi operasyonunun eşlik ettiği kronik aortoiliyak tıkaçıcı arter hastalıklı, lokal ve tümesan anestezi eşliğinde ekstra-anatomik baypas grefti operasyonu uyguladığımız 54 yaşındaki erkek hastayı sunmayı amaçladık.

**Anahtar Kelimeler:** Kritik bacak iskemisi, damar greftleme, tümesan anestezi

### ABSTRACT

Peripheral arterial circulatory disorders is an important cause of morbidity and mortality today. Extra-anatomic bypass operations in patients which have high risk for limb salvage are alternative methods that may be preferred. In this case, we aimed to present a 54 year-old male patient who underwent extraanatomic bypass graft surgery for chronic aortoiliac occlusive arterial disease under local and tumescent anesthesia because of to accompany with advanced stage chronic obstructive pulmonary disease and resting dyspnea, previous thoracic aortic surgery and migrated lumbar disc hernia operations.

**Keywords:** Critical limb ischemia, vascular grafting, anesthesia tumescent

İletişim / Correspondence:

Dr. Seyhan YILMAZ

SBÜ Derince Eğitim ve Araştırma Hastanesi, Kalp Damar Cerrahisi Kliniği, Kocaeli, Türkiye

E-mail: drlabarna@gmail.com

Başvuru Tarihi:29.03.2016

Kabul Tarihi:09.06.2016

## INTRODUCTION

Chronic occlusive peripheral arterial disease is defined as the hypoxia developing in an extremity due to reduction or cessation of blood flow and aorto-femoral, femoro-popliteal, or infrapopliteal arterial bypass grafting has an important role in the surgical treatment of this condition. Extra-anatomical arterial reconstructions may be performed between different body parts, are known to reduce morbidity and mortality rates in patients with occlusive peripheral arterial disease and comorbid conditions, and can be defined as surgical reconstructions aiming to provide blood flow to ischemic regions in clinical situations where bypass grafting at the anatomical location is risky or not feasible (1, 2). Also, extra-anatomical bypass (EAB) surgery has been shown to represent a good therapeutic alternative when abdominal graft anastomosis requiring laparotomy is associated with a high risk (1).

In this case report, a 54-year old male patient undergoing femoro-femoral bypass (FFB) under local and tumescent anesthesia in the surgical theatre with a pre-diagnosis of chronic iliac artery occlusion.

## CASE

This 54-year old male patient presented to our outpatient unit with complaints of coldness in the left foot, severe pain, and inability to walk for the past 3 months. He reported to experience left lower extremity pain with a walking distance of 200 m, and the detailed history suggested a worsening of his symptoms in the last 3 month period, with a walking distance of less than 50 meters and pain at rest. He was operated for aortic coarctation 16 years ago and he was currently on bronchodilators and oxygen inhalation therapy at home due to chronic obstructive pulmonary disease (COPD); also he had another surgical intervention 2 years ago due to lumbar disc herniation. Physical examination showed non-palpable femoral artery and distal pulses in the left lower extremity, while the femoral, popliteal and pedal arterial pulses were palpable on the right. The distal part of the lower extremity and the left foot were colder as compared to the right side, with mild cyanosis. No neurological deficits or motor power loss could be detected. The patient had stage III symptoms and

signs according to Fontaine's classification with an ABI of  $< 0.75$ . The patient had left thoracotomy and lumbar discectomy scar. He had resting dyspnea and oxygen requirement. BP was 150/80 mmHg, pulse rate was 92 bpm, respiratory rate was 26/min, oxygen saturation (with pulse oxymeter) was 82%. Preoperatively the patient was administered oxygen inhalation treatment. An arterial Doppler ultrasound examination of the lower extremities showed blood flow in the left femoral and popliteal arteries with monophasic flow pattern and a subsequent computed tomography of the thoraco-abdominal region showed occlusion in the left iliac artery (Figure 1).

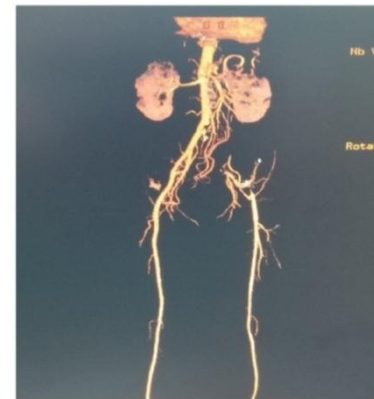


Figure.1. Preoperative CTA image

Based on history, physical examination and laboratory findings a diagnosis of occlusive peripheral arterial disease was made and the patient was admitted to the department of cardiovascular surgery for surgical treatment. A lumbar MRI and respiratory function tests (FEV1/FVC:59%, FEV1:41%) were performed and blood gases were analyzed under oxygen inhalation therapy (nasal cannula, 2 L/min; (pO<sub>2</sub>:63.8, pCO<sub>2</sub>:41.1). This patient with comorbid conditions was considered high-risk based on the assessments by the departments of Pulmonary Medicine, Neurosurgery, Cardiology, and Anesthesia and the patient refused to have spinal anesthesia; thus, a decision to perform FFB was made for the treatment of critical leg ischemia and the surgery was commenced under local anesthesia.

Under local anesthesia, both femoral arteries were explored (firstly the left) and common femoral arteries (CFA), superficial femoral arteries (SFA) and deep femoral arteries (PFA) were retracted.

Left CFA and its branches were observed to be atherosclerotic and hypoplastic as compared to the right, with no filling pressure in the pulse. Tumescence anesthesia in the suprapubic region was performed in order to place a vascular graft between both femoral arteries, and a PTFE vascular graft with a 7-mm ring could be passed through the subcutaneous tunnel prepared in this location without need for additional anesthesia, including the need for sedo-analgesia (this decision was based on consultation with the patient during surgery). After heparinization, distal and proximal vascular clamps were placed on both sides, first on the right, then an end-to-end anastomosis between the end of the vascular graft and right CFA was performed using 6/0 prolene sutures and the vascular clamps were removed. The length and tension of the graft were adjusted after ascertaining the absence of bleeding in the anastomosis line and presence of pulse and blood flow in CFA, SFA, PFA and the vascular graft. Next, vascular clamps were placed at CFA, SFA, and PFA and the other end of the graft was anastomosed to the left CFA using 6/0 prolene sutures with end-to-side anastomotic technique. Vascular clamps were removed and no bleeding occurred. Pulse could be obtained in the left CFA, SFA and PFA.

Postoperative treatment at the cardiovascular surgery service included fluid replacement, antibiotics, low molecular weight heparin (b.i.d. subcutaneously), anti-aggregating agents, and vasodilators with continuation of the treatment for COPD. The popliteal artery in the left lower extremity was palpable and blood flow could be detected by Doppler in the left ADP and ATP, with warming in the left foot and distal leg. A complete resolution of symptoms was observed and the patient was discharged on postoperative day 2 with medical treatment (due to transportation difficulty from his temporary residence to the hospital the following were prescribed: low molecular weight heparin (LMWH), anti-aggregating agents, and vasodilators). At postoperative day 10, he attended to outpatient unit for a control examination and he was found to have palpable lower extremity pulses. Anticoagulant treatment was commenced. A follow-up lower extremity CT angiography performed 3 months after surgery confirmed the

patency in the femoro-femoral vascular graft (Figure 2). Informed consent was obtained from the patient.

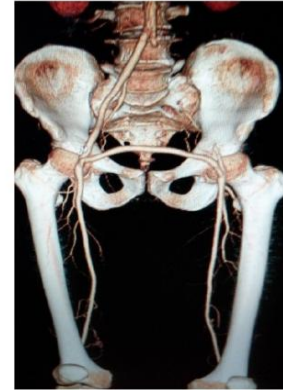

Figure.2. Postoperative CTA image

## DISCUSSION

Extra-anatomic bypass surgery with appropriate surgical technique and medical support is a viable alternative to anatomical bypass surgery with low rates of mortality and high rates of short- and long-term patency, particularly in high risk patients with ischemic lower extremities (1). Due to the high-risk status for general anesthesia owing to previous aortic coarctation surgery and COPD with severe dyspnea, a femoro-femoral bypass surgery was performed under local and tumescent anesthesia. Following surgical intervention LMWH, anticoagulants, anti-aggregating agents, and vasodilators were administered and recommended in order to prevent formation of graft thrombosis and to maintain longer graft patency.

EAB is particularly preferred as a less invasive strategy in patients with a history of laparotomic surgery, acute myocardial infarction, congestive heart failure, renal failure requiring hemodialysis, life expectancy of less than 2 years (e.g. malignancy, systemic disease), severe pulmonary failure with resting dyspnea and need for oxygen, and morbid obesity with a BMI of greater than 40 kg/m<sup>2</sup> (1). Similarly our patient was considered to have a high-risk status for aorto-femoral anatomic bypass surgery due to resting dyspnea, advanced COPD, and oxygen dependency, and therefore an EAB was considered appropriate and was performed under local and tumescent anesthesia. FFB should be the surgery of choice in high-risk patients with unilateral ilio-femoral occlusion if the

contra-lateral side is adequate angiographically and hemodynamically (2). In our patient, left iliac arterial occlusion was present and FFB was performed after confirmation of healthy vasculature in the donor site by CT angiography.

In 1980s major advances have been made in EAB surgery, particularly in axillo-bifemoral bypass grafting, after introduction of grafts with external support (ring). Previous studies have shown that patency rates in saphenous vein grafts and prosthetic dacron grafts used in EAB surgery are lower as compared to those with an external support and therefore currently grafts with external support are preferred in EAB surgery (3, 4). Thus, in our patient a PTFE vascular graft with a 7-mm ring support was used as the prosthetic graft material and 3 months after surgery, complete patency was found in the graft.

The technique of anesthesia also has an impact on morbidity and mortality, with superior results reported for local anesthesia than in other methods, particularly in patients with comorbidities (5). To our knowledge, no studies have reported FFB under local anesthesia previously. For instance in a study by Erentuğ V. et al. in 2003, all patients undergoing EAB had general anesthesia (2), and Kunt et al. reported the use of bypass surgery under epidural anesthesia in all of their patients in 2004 (6). Previous spinal surgery and presence of chronic back and low back pain are relative contraindications for this technique, and our patient with a previous history of lumbar disc surgery refused to have spinal anesthesia. In our unit, FFB surgery is performed under epidural anesthesia when general anesthesia is not feasible. Presence of a high-risk status for general anesthesia in conjunction with the presence of relative contraindications for spinal anesthesia and patient refusal of spinal anesthesia, local and tumescent anesthesia were successfully used for FFB surgery.

Previous studies have reported that patients may experience anxiety and intraoperative pain when the procedure is performed under local anesthesia, that additional sedoanalgesia may be administered, and that increased pH by addition of bicarbonate into the analgesic mixture may help decrease the intensity of pain during local anesthesia (5). In

peripheral vascular procedures performed under local anesthesia, anxiety and pain may not be sufficiently controlled despite use of adequate doses of local anesthesia, thus requiring additional sedoanalgesia. In our patient, adequate doses of local anesthesia were administered in both inguinal regions to prepare the femoral arteries along with administration of adequate doses of tumescent anesthetics with bicarbonate, precluding the need for additional anesthesia including sedoanalgesia.

Determination of appropriate type of anesthesia in surgery involving PAD may be challenging for the anesthesiologist and vascular surgeon due to the common presence of comorbid conditions. An increased risk of pulmonary complications and myocardial infarction has also been reported in patients undergoing infrainguinal bypass surgery under general anesthesia (7).

Capello et al., in their study in 2013, reported that they preferred local anesthesia for axillary access in axillofemoral bypass surgery and spinal anesthesia for femoral access in their elderly patients; they also proposed that local anesthesia may offer certain advantages in the elderly patients in terms of risk reduction, and risks associated general anesthesia may lead to prolonged and intensive postoperative care, emphasizing that their preferred approach may assist in the reduction of postoperative pulmonary and cardiac complications (8). We also have been able to successfully perform FFB surgery under local and tumescent anesthesia in this patient with comorbid conditions.

In patients with critical leg ischemia who are considered to have a high-risk status for general and spinal anesthesia, EAB surgery under local and tumescent anesthesia for limb salvage surgery should always be borne in mind as a therapeutic alternative with acceptable morbidity and mortality, and should probably be the preferred method of surgery for preventing the extremity amputation.

## REFERENCES

1. Saçar M, Onem G, Işıklı OY, Adalı F, Saçkan KG, Alşalaldehy M et al. Our intermediate and long-term results in the extra-anatomic bypass surgery. Pam Med J 2011;4:58-65.
2. Erentuğ V, Bozbuğa NU, Ömeroğlu SN, Erdoğan HB, Özen Y, Göksedef D et al. Extra-

Anatomic ByPass Procedures. Türk Göğüs Kalp Damar Cerrahisi Dergisi 2003;11: 42-45.

3. Manduz Ş, Berkan Ö, Çetin H, Katrancıoğlu N, Tünel A, Doğan K. Extra-Anatomic By-Pass Procedures. Turkish J Vasc Surg 2005; 14: 19-24.

4. Yetkin U, Akçay A, Özbek C, Biçeroğlu S, Karahan N, Gürbüz A. Our Axillo-femoral Extra-anatomic Bypass Grafts Applications. Turkish J Vasc Surg 2003; 12: 19-24.

5. Kahramansoy N, Büyükaşık O, Erkol H, Çöl C. Inguinal hernioraphy under local anesthesia in the elderly patients. Dicle Tıp Dergisi 2012; 39: 513-517.

6. Kunt AS, Darçın OT, Aydın S, Demir D, Andaç MH. Results of Extra-anatomic and Femoro-popliteal Bypass Surgery. Turkish J Vasc Surg 2004; 13: 11-15.

7. M Kim, J-Y Lee, Y-S Bang, I Shin, C Park. Monitored anesthesia care with remifentanyl for femorofemoral bypass graft patients. Korean J Anesthesiol 2011 August 61: 169-170.

8. E Cappello, M di Lorenzo, E Cutillo, E Franco. Axillofemoral bypass in elderly patients with local anesthesia: an alternative route to less risk. BMC Surgery 2013, 13:A6.