



Postpartum Thyrotoxicosis Coexisting with Acute Suppurative Thyroiditis Caused by Peptostreptococcus

Peptostreptokok Nedenli Akut Süpüratif Tiroidit ile Seyreden Postpartum Tirotoksikozis

Narin Nasıroğlu İmga, Yasemin Tütüncü, Mazhar Müslüm Tuna, Dilek Berker, Serdar Güler*

Ankara Numune Education and Research Hospital, Clinic of Endocrinology and Metabolism, Ankara, Turkey

*Hitit University Faculty of Medicine, Department of Endocrinology and Metabolism, Çorum, Turkey

Abstract

Acute suppurative thyroiditis (ST), which is usually caused by bacterial infection of the thyroid gland is a rare, but potentially life-threatening condition. The organisms most often isolated from acute ST patients are aerobic bacteria. Herein, we present a rare case of ST with thyroid abscess and thyrotoxicosis in the postpartum period caused by Peptostreptococcus. A 24-year-old female presented to our clinic on postpartum day 5 with severe neck pain when swallowing, chills and fever. Physical examination showed fever (38 °C), tachycardia, and an erythematous non-fluctuant mass over the left lobe of the thyroid. The results were compatible with hyperthyroidism due to thyroid tissue destruction. Ultrasonography (USG) of the thyroid showed a 10.1x14.5x25.6 mm heterogeneous hypoechoic lesion in the left lobe. Thyroid aspirate cultures showed Peptostreptococcus growth and because the sensitivity of it antibiotherapy was not changed. Two weeks later, thyroid USG showed that the abscess shrank to 2.2x3.1x4.2 mm. On the 20th day of antimicrobial therapy, all clinical and laboratory signs and symptoms of the infection were resolved. In the presented case, a rarely seen anaerobe Peptostreptococcus was isolated from the patient's thyroid abscess and she was treated with parenteral ampicillin/sulbactam therapy and multiple thyroid abscess aspirations. Thyrotoxicosis was resolved with no medications. During the follow-up period, the patient's prognosis was excellent and she had no complaints.

Keywords: Peptostreptococcus, postpartum thyrotoxicosis, suppurative thyroiditis

Öz

Akut süpüratif tiroidit (ST) genellikle tiroid glandının bakteriyel enfeksiyonunun neden olduğu, nadir görülen fakat hayatı tehdit edebilen bir durumdur. ST'li hastalardan izole edilen organizmalar aerobik bakterilerdir. Bu olgu sunumunda postpartum dönemde tiroid absesi ve tirotoksikozla gelen Peptostreptokokların neden olduğu, nadir görülen bir ST olgusunu sunduk. Yirmi dört yaşındaki bayan hasta kliniğimize postpartum 5. günde yutkunma ile şiddetlenen şiddetli boyun ağrısı, ateş ve titreme ile başvurdu. Fizik muayenede ateş (38 °C), taşikardi ve tiroid sol lobunda eritematöz, fluktuasyon vermeyen kitle tespit edildi. Tiroid dokusu hasarı nedeniyle geliştiği düşünülen tirotoksikoz saptandı. Tiroid ultrasonografide (USG) sol lobda 10,1x14,5x25,6 mm boyutunda heterojen hipoeoik lezyon bulundu. Tiroid aspirasyon kültüründe Peptostreptokok üredi. Uygulanan antibiyotiğe hassas olduğu için tedavi değiştirilmedi. İki hafta sonra yapılan USG'de absenin 2,2x3,1x4,2 mm boyutuna gerilediği görüldü. Antibiyotik tedavisinin 20. gününde enfeksiyonun tüm klinik ve laboratuvar bulguları düzeldi. Sunulan olguda hastanın tiroid absesinden nadir görülen anaerob bakteri olan Peptostreptokok izole edildi. Hasta parenteral ampisilin/sulbaktam tedavisi ve multipl tiroid abse aspirasyonu ile tedavi edildi. Tirotoksikoz tedavisiz düzeldi. Takip periyodunda hastanın prognozu mükemmeldi ve şikayeti yoktu.

Anahtar kelimeler: Peptostreptokok, postpartum tirotoksikozis, süpüratif tiroidit

Introduction

Acute suppurative thyroiditis (ST) is primarily caused by bacterial infection of the thyroid gland and is a rare, but potentially life threatening condition (1). It is a rare disease because of the rich blood flow and lymphatic drainage, high iodine content and protective fibrous capsule of the thyroid gland (2). Acute ST accounts for 0.1-0.7% of all cases of thyroiditis (3). The organisms most often isolated from ST patients are aerobic bacteria, whereas

anaerobic bacteria, viruses, and parasites are encountered infrequently. The disease presents with sudden onset pain, and tender and warm swelling in the anterior region of the neck (1). Patients with initially suspected ST should be evaluated via ultrasonography (USG). Neck USG often shows abscess formation and facilitates guided drainage when necessary (4). If there is clinical or sonographic evidence of abscess formation, fine needle aspiration for culture must be performed. Herein, we present a case of ST with thyroid abscess accompanied by thyrotoxicosis on

postpartum period caused by Peptostreptococcus, which is also rarely encountered.

Case Report

A 24-year-old female presented to our clinic on postpartum day 5 with severe neck pain when swallowing, chills and fever. She had been diagnosed with acute tonsillitis 6 days before delivery and had used oral amoxicillin for 5 days. Physical examination revealed fever (38 °C), tachycardia, and an erythematous non-fluctuant mass over the left thyroid lobe. Laboratory findings were as follows: elevated white blood cell count: 14.490 (neutrophils 85%); erythrocyte sedimentation rate: 30 mm/h; C-reactive protein (CRP): 127 mg/L. Thyroid function test results were as follows: free T4 (thyroxine): 3.12 ng/dL (normal range: 0.93-1.7); free T3 (triiodothyronine): 6.72 pg/mL (normal range: 2.0-4.4); thyroid-stimulating hormone (TSH): 0.01 µIU/mL (normal range: 0.27-4.2) (Table 1). Thyroid USG showed a heterogeneous hypoechoic lesion measuring 10.1x14.5x25.6 mm in the left lobe (Figure 1). Technetium-99m (^{99m}Tc) sodium pertechnetate neck scan showed no uptake in the thyroid beds (Figure 2). The results were compatible with thyrotoxicosis due to thyroid tissue destruction. There were no parenchymal changes that might hint the existence of other conditions causing thyrotoxicosis.

Approximately 5 cc of purulent yellow-brown foul-smelling fluid was obtained at the first USG-guided aspiration, the portion of which was cultivated. The patient was administered sulbactam/ampicillin for initial therapy. USG-guided aspirations had to be repeated three more times. Thyroid aspirate cultures showed Peptostreptococcus growth which was sensitive to sulbactam/ampicillin. Two weeks later, thyroid USG showed that the abscess shrank to 2.2x3.1x4.2 mm. On the 20th day of antimicrobial therapy, all clinical and laboratory signs and symptoms of infection were resolved and antibiotic therapy was discontinued.

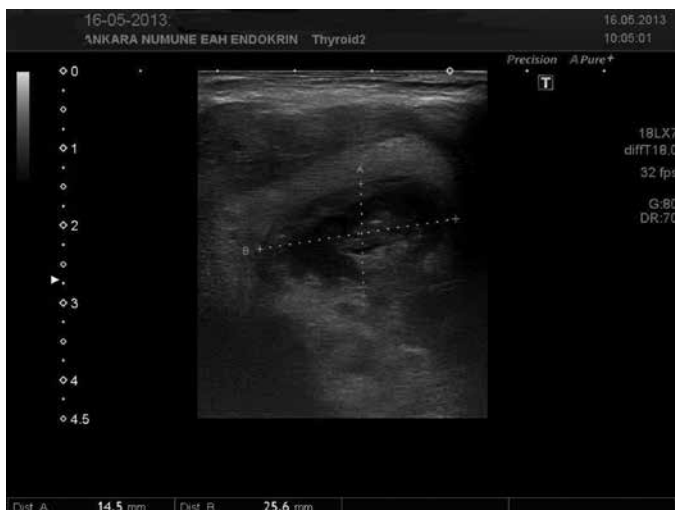

Figure 1. The ultrasonographic appearance of the heterogeneous hypoechoic lesion in the left lobe

Discussion

The thyroid gland is relatively resistant to infections. Most ST patients have predisposing conditions. Studies on adults with ST have reported that a history of goiter or adenoma in the thyroid gland was common (5). The organisms most often isolated from ST in children are Staphylococcus aureus, followed by S. pyogenes, S. epidermidis, and S. pneumoniae, in descending order of frequency (6). When anaerobic bacteria, such as anaerobic gram-negative bacilli and Peptostreptococcus spp. are isolated from an infected thyroid, they tend to be members of the oropharyngeal flora (1). Some viruses and parasites have been found to associate with ST. In this case, ST and abscess had probably developed after an upper respiratory tract infection via direct invasion of Peptostreptococci which may have been facilitated by maternal immune adaptation.

Fever, chills, erythema, sore throat, dysphagia, and dysphonia can be associated with ST. Symptoms develop over the course of days to a few weeks (18 d). Most cases develop following an upper respiratory tract infection. Leukocytosis, an elevated erythrocyte sedimentation rate, and elevated CRP are usually present (6). On physical examination, the thyroid gland is swollen and tender. Reactive lymphadenopathy may occur if the disease progresses. A single lobe, either lobes, or only the isthmus of the thyroid may be involved. The infection preferentially involves the left lobe in 90% of cases (6). In our case, abscess was revealed on the left side of thyroid gland.

ST should be differentiated from subacute granulomatous thyroiditis, malignancy, intracystic hemorrhage, and painful Hashimoto's thyroiditis. The diagnosis of ST should be confirmed via laboratory findings. T4, T3, and TSH levels are generally normal. The presence of thyrotoxicosis does not preclude a diagnosis of ST. In a series of children with ST, 93% had normal thyroid function test results, 4% were hyperthyroid, and 2% were hypothyroid (7). An adult ST series reported that 83% of patients

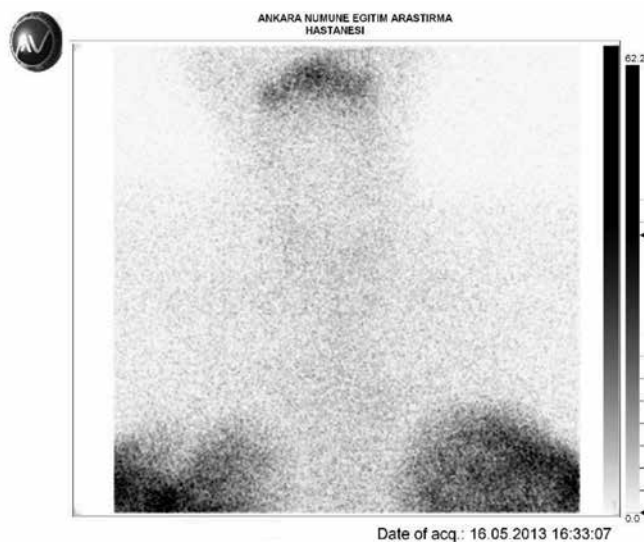


Figure 1. The Technetium-99m sodium pertechnetate neck scan showed no uptake in the thyroid beds

with bacterial thyroiditis had normal thyroid function test results (8). In the presented case, thyroid function test results were initially consistent with overt hyperthyroidism, but following appropriate therapy, it come back to normal ranges.

The management of acute ST with abscess initially includes antibiotic therapy and drainage. For empiric antibiotic therapy, clindamycin, penicillin with a beta-lactamase inhibitor, carbapenems, or metronidazole can be given. In the presented case, a rarely seen anaerobe "Peptostreptococcus" was isolated from the patient's thyroid abscess and she was treated successfully with parenteral sulbactam/ampicillin therapy and multiple thyroid abscess aspirations. In their review, Berger et al. (9) have reported that in the absence of treatment, the fatality rate was 12.1%. In our case, thyrotoxicosis has resolved with no medications. The patient was examined for anatomical deformity after the delivery. No anatomical deformity was found. During the follow-up period the patient's prognosis was excellent with no complications.

Authorship Contributions

Informed Consent: Consent form was filled out by all participants, Concept: Narin Nasirođlu İmga, Dilek Berker, Design: Narin Nasirođlu İmga, Yasemin Tütüncü, Data Collection or Processing:

Mazhar Müslüm Tuna, Analysis or Interpretation: Narin Nasirođlu İmga, Dilek Berker, Serdar Güler, Literature Search: Narin Nasirođlu İmga, Writing: Narin Nasirođlu İmga, Serdar Güler, Peer-review: Externally peer-reviewed, Conflict of Interest: No conflict of interest was declared by the authors, Financial Disclosure: The authors declared that this study has received no financial support.

References

1. Paes JE, Burman KD, Cohen J, Franklyn J, McHenry CR, Shoham S, Kloos RT. Acute bacterial suppurative thyroiditis: a clinical review and expert opinion. *Thyroid* 2010;20:247-255.
2. Brook I. Microbiology and management of acute suppurative thyroiditis in children. *Int J Pediatr Otorhinolaryngol* 2003;67:447-451.
3. John L, Hennessey J. "Acute and subacute, and reidel's thyroiditis." In: Leslie J, Groot D, eds. *The thyroid and its diseases* (6th ed). New York; Elsevier; 1996.
4. Naik KS, Bury RF. Imaging the thyroid. *Clin Radiol* 1998;53:630-639.
5. Gaafar H, El-Garem F. Acute thyroiditis with gas formation. *J Laryngol Otol* 1975; 89:323-327.
6. Jeng LB, Lin JD, Chen MF. Acute suppurative thyroiditis: a ten-year review in a Taiwanese hospital. *Scand J Infect Dis* 1994;26:297-300.
7. Rich EJ, Mendelman PM. Acute suppurative thyroiditis in pediatric patients. *Pediatr Infect Dis J* 1987;6:936-940.
8. Yu EH, Ko WC, Chuang YC, Wu TJ. Suppurative acinetobacter baumannii thyroiditis with bacteremic pneumonia: case report and review. *Clin Infect Dis* 1998;27:1286-1290.
9. Berger SA, Zonszein J, Villamena P, Mittman N. Infectious diseases of the thyroid gland. *Rev Infect Dis* 1983;5:108-122.